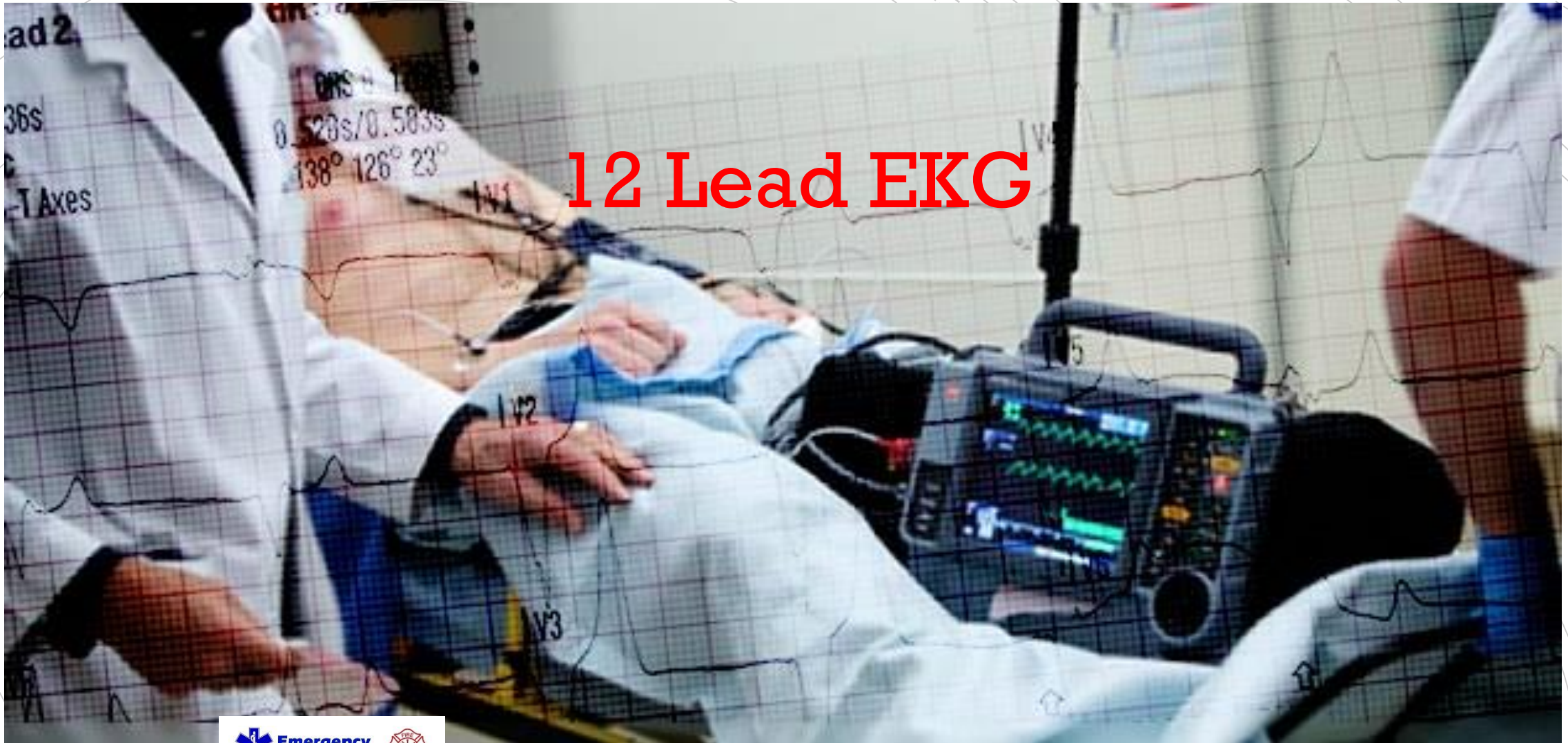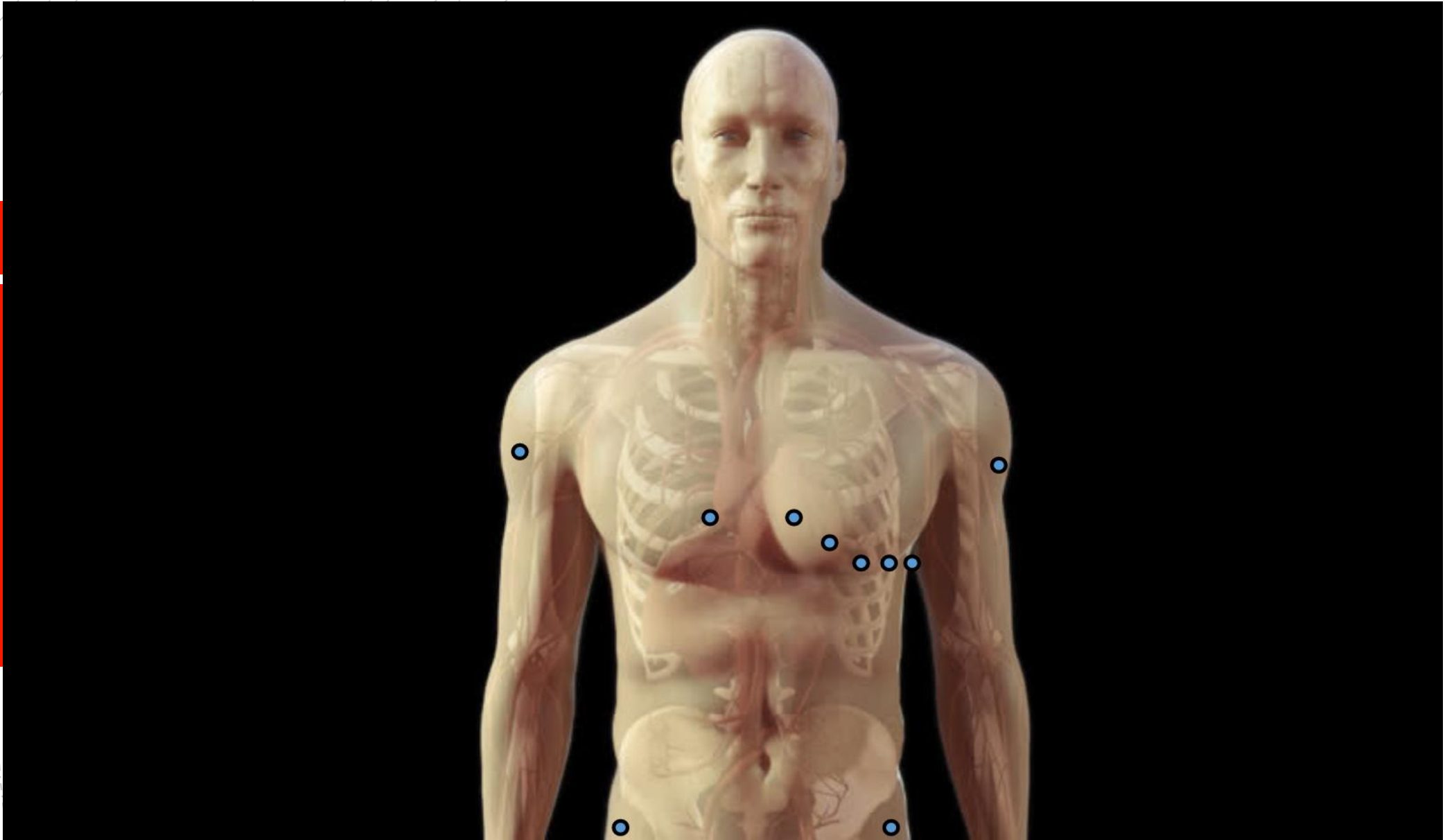
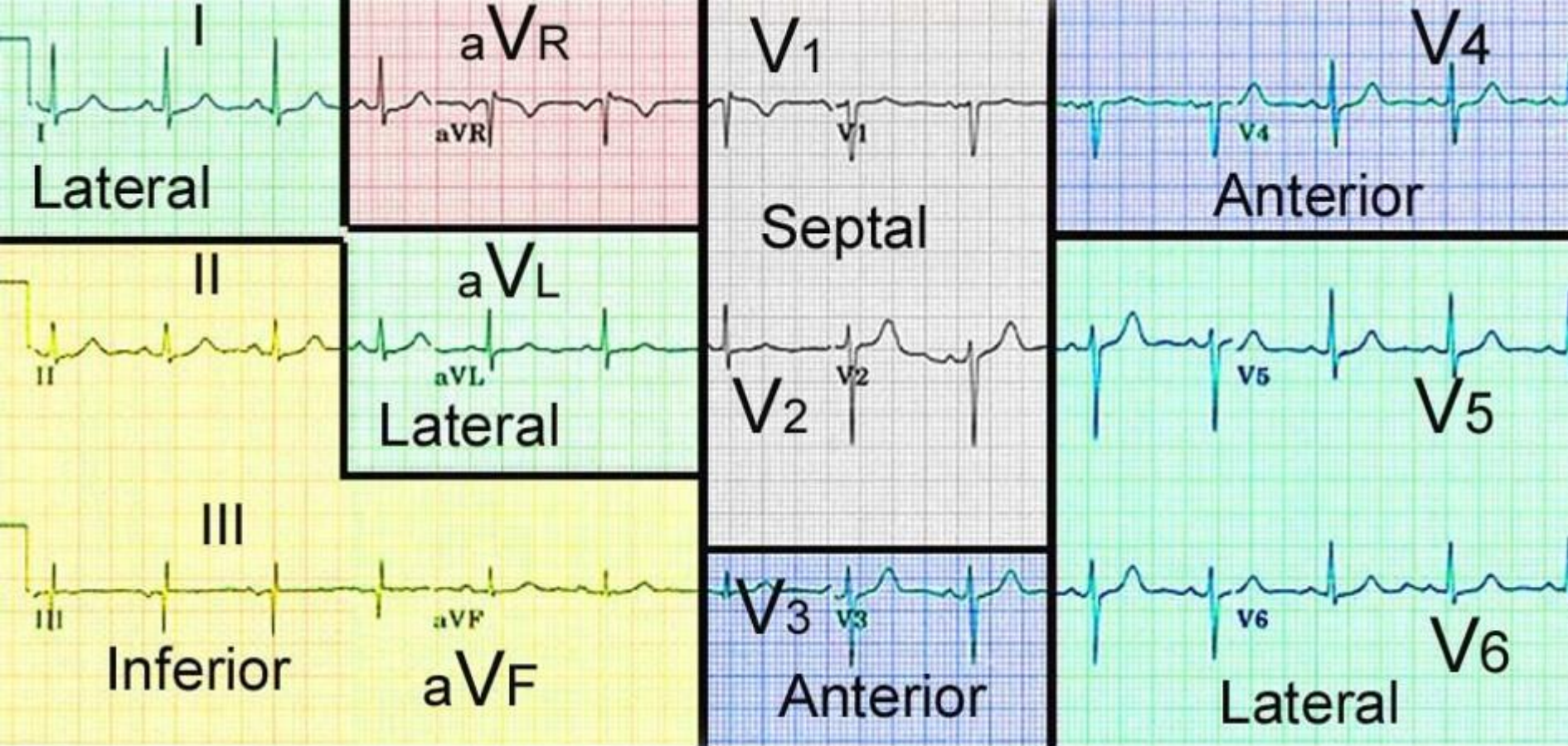


# Acute Coronary Syndrome







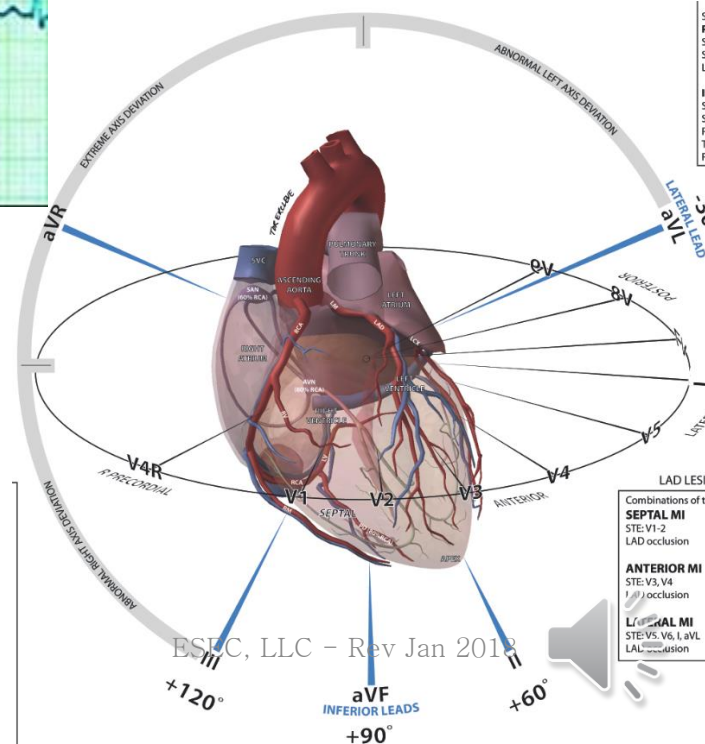
## Location

Anterior  
Anterolateral  
Lateral  
High lateral  
Inferior  
Inferolateral  
True posterior

## Leads

I, V<sub>2</sub>, V<sub>3</sub>, and V<sub>4</sub>  
I, aVL, V<sub>5</sub>, and V<sub>6</sub>  
V<sub>5</sub> and V<sub>6</sub>  
I and aVL (often with V<sub>5</sub>, V<sub>6</sub>)  
II, III, and aVF  
II, III, aVF, and V<sub>6</sub>  
Reciprocal changes in V<sub>1</sub> and V<sub>2</sub>

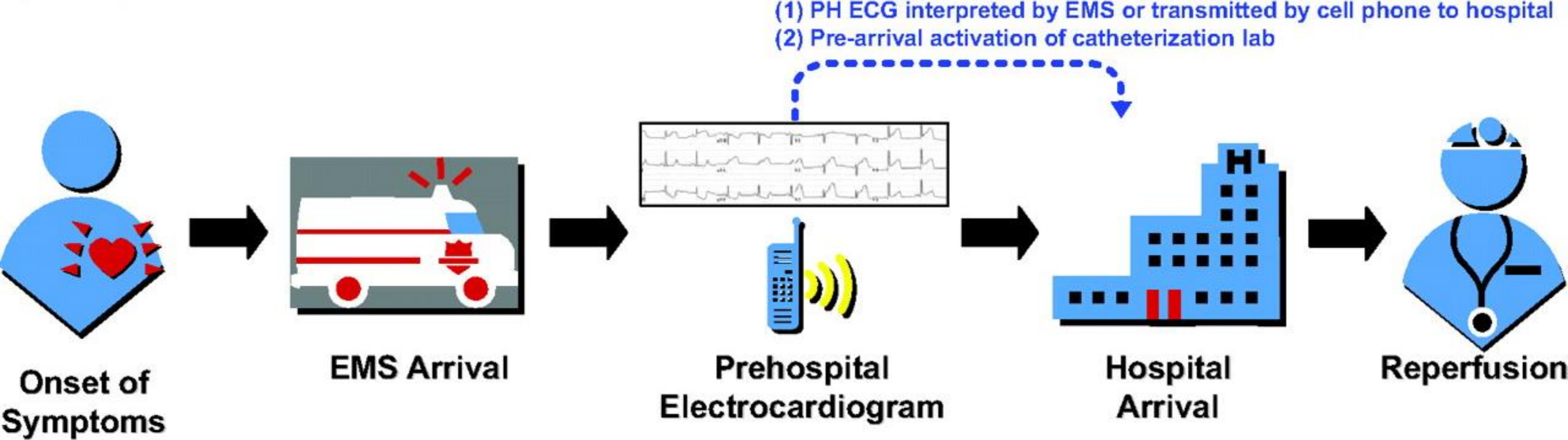
ction



# Disease Findings

- Chamber Enlargement
  - Atrial Enlargement
  - Ventricular Hypertrophy
  - Causes
    - Right-sided enlargement and hypertrophy, usually secondary to long-term pulmonary disease
    - Left-sided enlargement and hypertrophy, usually secondary to long-term hypertension





Recap

